

## Dexamethasone Adjunct in Ultrasound Guided Femorosciatic Block for Postoperative Analgesia in Below Knee Lower Limb Orthopedic Surgeries

Shweta Mahajan<sup>1</sup>, Anshit Abhi Pathania<sup>2</sup>

<sup>1</sup>Associate Professor, <sup>2</sup>Senior Resident, Dept of Anesthesia, Indira Gandhi Medical College, Shimla, Himachal Pradesh 171001, India.

### Abstract

**Background and Aims:** Since femoral sciatic block is not as famous as brachial plexus block for upper limb, and postoperative pain management in lower limb surgeries is limited to adjuvant in subarachnoid block or epidural analgesia. We intended to study the efficacy of ultrasound guided femorosciatic block in providing adequate postoperative analgesia, in patients undergoing below knee orthopedic surgeries. Also dexamethasone has been proved to be a useful adjuvant with local anesthetics in upper limb blocks, we considered to be studied in this block too. **Methods and Materials:** After approval of the institutional ethics committee, 65 patients planned for elective below knee orthopedic surgeries were enrolled in the study. Patients were randomly allocated to two groups: Group L and Group D. All the patients received subarachnoid block with 15 mg (3 ml) of 0.5% heavy bupivacaine for the surgery. In postoperative recovery room, when the level regressed to T10 level, ultrasound guided femorosciatic block was given. Group L received 20 ml of 0.25% levobupivacaine + 1 ml NS in femoral nerve block and 20 ml of 0.25% levobupivacaine + 1 ml NS in sciatic nerve block. The Group D received 20 ml of 0.25% levobupivacaine + 4 mg (1 ml) dexamethasone in femoral nerve block and 0.25% levobupivacaine + 4 mg (1 ml) dexamethasone in sciatic nerve block. In the postoperative period analgesia was given only on demand. The time of receiving first rescue analgesia was recorded along with the total number of rescue analgesics required in the 24 hours. The postoperative adductor muscle weakness and day of ambulation was also noted. **Results:** The demographic profiles of all the patients were similar. The postoperative analgesia was longer in Group D and also the number of rescue analgesics required in 24 hours was lesser in Group D. No patient had any block related or drug related side effects. **Conclusion:** Ultrasound guided femorosciatic block provides propitious postoperative analgesia in below knee orthopedic surgeries and can be used for providing postoperative analgesia in below knee orthopedic surgeries, without any side effects. Furthermore, adding dexamethasone to the block helps in prolonging the efficacy of the block by increasing the duration of analgesia provided and reducing the number of rescue analgesics required.

**Keywords:** Femorosciatic block; Levobupivacaine; Dexamethasone.

### How to cite this article:

Shweta Mahajan, Anshit Abhi Pathania. Dexamethasone Adjunct in Ultrasound Guided Femorosciatic Block for Postoperative Analgesia in Below Knee Lower Limb Orthopedic Surgeries. Indian J Anesth Analg. 2019;6(5 P-II):1822-1827.

### Introduction

The introduction of ultrasonography in anesthesiology has been a captivating tool for the anesthesiologist. Peripheral nerve blocks have regained its importance owing to the much more

safety provided by the ultrasound due to direct visualization of the nerve roots, needle and drug distribution.

Femorosciatic block is the most useful block for lower limb but has not been that popular owing to the technical difficulty of the blind blocks. Use of high

**Corresponding Author:** Anshit Abhi Pathania, Senior Resident, Dept of Anesthesia, Indira Gandhi Medical College, Shimla, Himachal Pradesh 171001, India.

**E-mail:** [apathania26@gmail.com](mailto:apathania26@gmail.com)

**Received on** 13.05.2019, **Accepted on** 19.06.2019

resolution ultrasound has helped in identification of these nerves and facilitate the deposition of drug around the nerves.<sup>1</sup> It has been found, in a recent Cochrane review on USG for upper and lower limb block by Lewis SR and colleagues, that ultrasound guidance produces superior peripheral nerve block success rates along with reduction in complications such as nerve damage. They also suggest that it takes less time to perform the block when using ultrasound techniques alone rather than nerve stimulation.<sup>2</sup>

Effective post operative analgesia in orthopedic surgeries allows early mobilization and physiotherapy which hastens the overall patient recovery. The postoperative complications such as thromboembolic complications and nosocomial infections, and hospital stay is also reduced provided adequate post operative analgesia in patients.<sup>3</sup> The search for ideal postoperative analgesia regimens following lower limb surgical procedures still continues till today, that would facilitates high quality analgesia with minimal complications in the postoperative period.<sup>4</sup>

The three most common alternatives for anesthesia or analgesia for lower limb orthopedic surgeries include spinal anesthesia, epidural anesthesia and the femorosciatic nerve blocks. It is generally accepted that both peripheral nerve blocks and spinal anesthesia provide sufficient anesthesia, better postoperative analgesia and satisfaction than general anesthesia, in addition to being minimally invasive and using less resources. But spinal block most of the times is associated with hemodynamic changes, making it unsuitable for high-risk patients.<sup>5</sup>

The second alternative is continuous epidural anesthesia or patient controlled epidural analgesia with promising results in managing post operative pain. A study by Osaka *et al.* comparing continuous sciatic nerve block and epidural analgesia for postoperative pain control in patients with fracture of the foot concluded that continuous sciatic nerve block developed good postoperative analgesia in these patients compared with continuous epidural.<sup>6</sup>

Therefore, femorosciatic blocks are being focused upon nowadays as the regional anesthetic technique following lower limb orthopedic surgeries, which are two of the most common blocks applied either in combination or alone.<sup>7</sup> Tran *et al.* compared femorosciatic nerve block with intraarticular infiltration in children undergoing Anterior Cruciate Ligament reconstruction. They found that femorosciatic nerve block provides better postoperative analgesia with fewer side effects.<sup>8</sup>

Many local anesthetics have been used in peripheral nerve blocks, of which bupivacaine,

levobupivacaine and ropivacaine provide long duration of analgesia.

In a comparative study done by Fanelli and colleagues, ropivacaine, bupivacaine and mepivacaine were compared in femorosciatic block. They found no differences in the quality of sciatic nerve block as well as in the nerve block resolution times observed among the three groups.<sup>9</sup> Compared to ropivacaine, levobupivacaine provides significantly longer duration of analgesia.<sup>10</sup> Longer duration of sensory block along with less toxicity makes levobupivacaine a better choice for peripheral nerve blocks.<sup>11</sup>

Dexamethasone is a glucocorticoid with anti-inflammatory properties and has been used proficiently in various peripheral nerve blocks. It has been suggested in Cochrane Review by Pehora and colleagues that both perineural and intravenous dexamethasone may prolong duration of sensory block and are effective in reducing postoperative pain intensity and opioid consumption when used as an adjuvant to peripheral nerve block in upper limb surgery.<sup>12</sup> It has been studied with intrathecal levobupivacaine for labor analgesia and has been concluded to prolong the duration of levobupivacaine.<sup>13</sup> This combination of levobupivacaine and dexamethasone has also proven to be useful combination in axillary brachial plexus block<sup>14</sup>, but has not been studied in lower limb blocks.

Therefore, we selected this useful combination in femorosciatic block for the overall patient satisfaction and better postoperative analgesia in below knee orthopedic surgeries.

## Materials and Methods

After approval by institutional ethical committee, this study was carried out on 65 patients of both sex of ASA I-II physical status and in the 20–60 age group, who were scheduled for below knee orthopedic surgeries, between May 2018 and October 2018. The patients excluded were those with history of cardiac, renal or hepatic disease, CNS disorders, neuropathy, chronic treatment with calcium channel blockers. The patients having bleeding disorders, hypersensitivity to local anesthetics, local infection at the site where needle for block is to be inserted and allergic to study drugs or patient refusing the procedure were also excluded from the study. It was a prospective, double blinded controlled trial study. The study drug solution was prepared and given to the investigator by a nonparticipant staff. After explaining the procedure to the patients and

getting the informed consent, the patients were divided into two groups; Group L and Group D using random number chart.

Group L received 20 ml of 0.25% levobupivacaine + 1 ml NS in femoral nerve block and 20 ml of 0.25% levobupivacaine + 1 ml NS in sciatic nerve block. The Group D received 20 ml of 0.25% levobupivacaine + 4 mg (1 ml) dexamethasone in femoral nerve block and 0.25% levobupivacaine + 4 mg (1 ml) dexamethasone in sciatic nerve block.

All patients were kept nil orally for at least six hours before the procedure. They were given premedication in the form of tablet Alprazolam 0.5 mg and tablet Ranitidine 150 mg at 6:00 am on the day of surgery and were tested for Lignocaine sensitivity. On arrival to operation theatre, monitorings (i.e. five lead ECG, NIBP, SpO<sub>2</sub>) were established along with starting of peripheral intravenous line in contra lateral hand with 18G IV canula. Baseline parameters were noted. All patients included in study were given subarachnoid block (SAB) in sitting position using 26G Quincke's spinal needle in L3-L4 interspinous space with 15 mg of 0.5% hyperbaric bupivacaine after free flow of CSF. After confirmation of adequate level (T6-T8), surgeon was allowed to proceed. After completion of surgery and covering of incision with the dressing, level of subarachnoid block was assessed in the patient in the recovery room. Once the level is regressed to T10, after proper positioning of patient, USG guided femoral and sciatic nerve block was given in allocated patients with respective drug solutions.

Under all aseptic precautions the inguinal area was draped, using linear probe (6-13 MHz frequency) of ultrasound, with sufficient application of sterile gel, a short axis view of femoral nerve and vessel was identified (Femoral nerve lies lateral to femoral artery in a groove formed by Iliacus and Psoas muscle). A 22G ecogenic needle was used by an ultrasound guided in-plane (lateral to medial) technique and positioned between the fascia iliaca and iliopsoas muscle near lateral corner of femoral nerve. After checking the exact location of the needle tip, drug solution was injected slowly to open the plane and drug distribution was seen as hypoechoic area.

Sciatic nerve block was given in supine position by same ultrasound probe. Leg of the patient was abducted and externally rotated so that the popliteal fossa was exposed for the access of probe. After draping popliteal fossa and applying sufficient gel, a short axis view of popliteal neurovascular bundle was obtained. A 22G ecogenic needle was used

by ultrasound guided in-plane (lateral to medial) technique and under continuous ultrasound guidance, its tip was placed between the tibial and common peroneal component of sciatic nerve near the division and the drug was injected and drug distribution was confirmed.

The hemodynamics were measured continuously up to 2 hours in the recovery room and monitored for any side effects. The patients were then shifted to postoperative ward. Hemodynamics, pain and VRS was evaluated by the blinded investigator at 0, 2, 4, 8, 12 and 24 hours and the time of first rescue analgesia was noted. For the first 24 hours, the protocol for postoperative analgesia consisted of standard orders for i.v. diclofenac 75 mg on demand for VRS > 4. For breakthrough pain, patients were treated with IV tramadol 100 mg as and when required.

Patients were asked to rate average pain they experience over 24 hrs post operatively on a 10 cm VRS b/w 0-No pain and 10-Very severe pain.

After 24 hrs the patients were assessed for adductor muscle weakness by sideways leg raising test in which 0-Able to raise the leg sideways and maintain it for 10 seconds or more, 1-Able to raise leg sideways but for less than 10 seconds but more than 5 seconds and 2-Not able to raise the leg sideways or able to raise less but less than 5 seconds. The patients with score of 2 were taken as adductor muscle weakness present.

The patients were encouraged for embolization after 24 hours and were encouraged to perform 10 meter walk test, with the help of walking aid (as advised by Orthopedician). The day of completion of 10 meter walk test was taken as day of start of embolization.

The data was collected and entered in MS EXEL 2010. Statistical analysis was performed using SPSS software 17. The one sample Kolmogorov Smirnov test was employed to determine whether data sets differ from a normal distribution. Normally distributed data was analyzed using a repeat measures general linear model analysis of variance, whereas non normally distributed data was analysed using Mann-Whitney U test and categorical data was analyzed using chi-square test. Level of significance "*p*" was considered significant < 0.05.

## Results

The total of 65 consenting patients were enrolled in the study. Out of the 65 patients, 2 were excluded due to inadequate sonographic anatomy, 1 patient was excluded due to lost follow up in postoperative

period and 2 were excluded due to inadvertent rescue analgesics (dosage without need). Sixty patients were randomly divided into the 2 groups (Group L and Group D). The demographic profile was comparable in both the groups ( $p > 0.05$ ) (Table 1).

The postoperative hemodynamics and respiration were stable in both the groups and were comparable, with no major side effects noticed in any of the two groups.

The duration of analgesia was significantly longer in Group D and thereby the number of rescue analgesics required were less in Group D with early ambulation recorded in the group ( $p < 0.05$ ) (Table 2) (Fig. 2).

On comparing the adductor muscle weakness score, no patient in any of the two groups had adductor muscle weakness, i.e., score of more than 1.

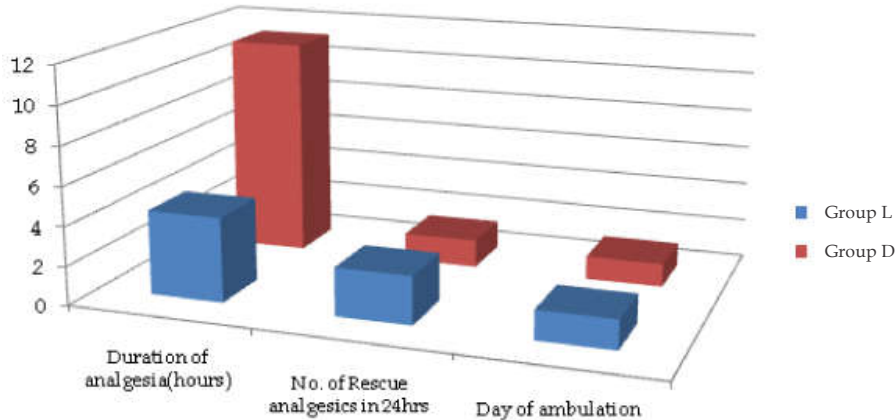


Fig. 1:

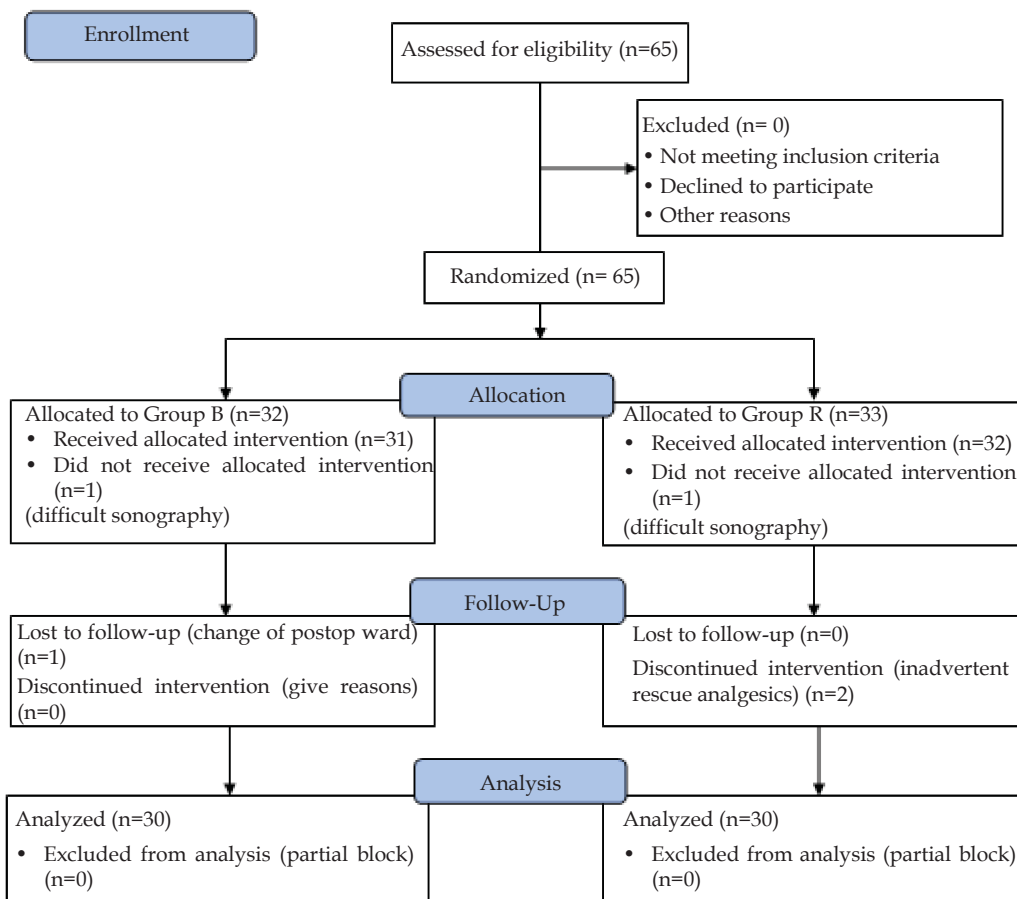


Fig. 2: Consort Flow Diagram

**Table 1:** Demographic Profile

	Group L	Group D	p value
Age (yrs)	40.87 ± 13.161	44.97 ± 15.897	.281
Weight (kg)	58 ± 6.181	57.53 ± 7.851	.799
Height (m)	1.60 ± 0.058	1.576 ± 0.092	.130
BMI (kg/m <sup>2</sup> )	22.44 ± 2.306	22.13 ± 2.159	.240

**Table 2:** Comparison of duration of analgesia and postoperative ambulation

	Group L	Group D	p value
Duration of analgesia (minutes)	290.83 ± 24.986	673.50 ± 69.928	0.000
No. of rescue analgesics (24 hr)	2.47 ± .571	1.43 ± .568	0.000
Day of ambulation	1.50 ± 0.509	1.20 ± .407	0.015

## Discussion

We have overlooked lower limb blocks for providing analgesia since decades. In our study, with the help of ultrasound guidance the femoral and sciatic nerves could be easily demarcated. Only 2 of the 65 patients had difficult sonographic anatomy and hence were excluded from the study. No block related side effects were noted, with no reports of adductor muscle weakness seen in any of the patients of the two groups.

On the other hand dexamethasone has been an integral part of anesthesiology, used for its anti-inflammatory and antiemetic action since ages. Even though its effect as adjuvant in peripheral nerve blocks is not fully understood, it has been proved to be a promising adjuvant.<sup>12</sup> Its anti-inflammatory and analgesic effects are through the inhibition of phospholipase A2 and activation of glucocorticoid receptors. The perineurally administered dexamethasone has been demonstrated to inhibit signal transmission of nociceptive C-fibers, decrease ectopic neuronal discharge, and decrease the release of local inflammatory mediators.<sup>15,16</sup>

In a meta-analysis done by Choi *et al.*, they concluded that adding dexamethasone to long acting local anesthetics prolongs the mean analgesic duration. They found no statistically significant difference in opioid consumption and no reported dexamethasone-induced neuronal damage.<sup>17</sup> In lower extremity nerve blocks studied by Fredrickson *et al.*, patients receiving 8 mg dexamethasone in sciatic nerve block reported lower pain score at 24 hours, but patients receiving dexamethasone in ankle nerve block had no added advantage.<sup>18</sup> However our study shows adding dexamethasone provided longer analgesia with lower requirement of parenteral analgesics

in post operative period. In another study done by Rahangdale *et al.*, compared intravenously versus perineurally administered dexamethasone, it was concluded that perineural dexamethasone prolonged the duration of analgesia and motor blockade compared with the control group.<sup>19</sup>

The combination of levobupivacaine with dexamethasone has been studied in many upper limb blocks, which concluded that the combination provides longer duration of analgesia compared to levobupivacaine alone, and also reduces the rescue analgesics requirement.<sup>20-23</sup> The results are similar to our study, but the combination of femoral sciatic block has never been studied before. Another similar study done by Akkaya *et al.*, used 30 ml of 0.25% levobupivacaine with 8 mg dexamethasone for bilateral transversus abdominis plane block, concluded that there was significant reduction in postoperative opioid consumption, and this combination may be used as alternative to epidural opioid analgesia.<sup>24</sup>

Hence, the combination of levobupivacaine with dexamethasone is useful combination in femoro sciatic block too.

The limitation of our study was difficulty in achieving optimal limb positioning for the sciatic nerve block, for which an assistant was required to hold the patients leg in abduction and external rotation. Another limitation was the adductor muscle weakness was tested after 24 hours, at which the effect of block was weaned off.

## Conclusion

The following conclusions were drawn from the study:

1. Ultrasound guided femorosciatic block provides propitious postoperative analgesia in below knee orthopedic surgeries. No patients in any of the studied groups had block related side effects.
2. The duration of analgesia was longer when dexamethasone was combined with levobupivacaine for the block and the need of rescue analgesics was also lesser in the group. Also combining dexamethasone resulted in early ambulation and better patient satisfaction.

## References

1. Gray AT. Ultrasound guided regional anesthesia current state of art. *Anesthesiology*. 2006;104:368-73.

2. Lewis SR, Price A, Walker KJ, *et al.* Ultrasound guidance for upper and lower limb blocks (Review). *The Cochrane Library*. 2015;9:22.
3. Choi P, Bhandhari M, Scott K, *et al.* Epidural analgesia for pain relief following hip or knee replacement. *Cochrane Database of Systemic Reviews*. 2003;3:CD003071.
4. Williams BA, Kanter ML, Vogt MT. Economics of nerve block pain management after anterior cruciate ligament reconstruction: potential hospital cost savings via post-anesthesia care unit bypass and same day discharge. *Anesthesiology*. 2004;100:697-706.
5. Montes FR, Zarate E, Grueso R. Comparison of spinal anesthesia with combined sciatic-femoral nerve block for outpatient knee arthroscopy. *J Clin Anesth*. 2008;20:415-20.
6. Osaka Y, Shimada N, Saito R, *et al.* A clinical comparison of continuous sciatic nerve block and epidural anesthesia for postoperative pain control in patients with fracture of the foot. *Masui*. 2015;64(4):388-91.
7. O'Donnell BD, Iohom G. Regional Anesthesia techniques for ambulatory orthopedic surgeries. *Current opinion in Anesthesiology*. 2008 Dec;21(6):723-8.
8. Tran KM, Ganley TJ, Wells L, *et al.* Intraarticular bupivacaine-clonidine-morphine versus femoral - sciatic nerve block in paediatric patients undergoing anterior cruciate ligament reconstruction. *Anesth Analg*. 2005;101:1304-10.
9. Santorsola R, Casati A, Cerchierini E, *et al.* Levobupivacaine for peripheral blocks of the lower limb: a clinical comparison with bupivacaine and ropivacaine. *Minerva Anesthesiol*. 2001;67:33-6.
10. Cacciapuoti A, Castello G, Francesco A. Levobupivacaina, bupivacainaracemica e ropivacainanel blocco del plesso brachiale. *Minerva Anesthesiol*. 2002;68:599-605.
11. Piangatelli C, De Angelis C, Pecora L, Recanatini F, Cerchiara P, Testasecca D. Levobupivacaine and ropivacaine in the infraclavicular brachial plexus block. *Minerva Anesthesiol*. 2006;72:217-21.
12. Pehora C, Pearson AM, Kaushal A, *et al.* Dexamethasone as an adjuvant to peripheral nerve block. *Cochrane Database Syst Rev*. 2017 Nov 9;11:CD011770.
13. Wahdan AS, El-Sakka AI, Gaafar HMI. The effect of addition of dexamethasone to levobupivacaine in parturients receiving combined spinal-epidural for analgesia for vaginal delivery. *Indian journal anaesth*. 2017;61(7):556-61.
14. Kilinc LT, Hanci A, Sivrikaya GU *et al.* Comparison of 0.5% Levobupivacaine and 0.5% Levobupivacaine + dexamethasone on Axillary Brachial Plexus Blockade. *Regional Anesth and Pain Medicine*. 2008;33(5):66.
15. Johansson A, Hao J, Sjolund B. Local corticosteroid application blocks transmission in normal nociceptive C-fibres. *Acta Anesthesiol Scand*. 1990;34(5):335-8.
16. Eker HE, Cok OY, Aribogan A, Arslan G. Management of neuropathic pain with methylprednisolone at the site of nerve injury. *Pain Med*. 2012;13(3):443-51.
17. Choi S, Rodseth R, McCartney CJ. Effects of dexamethasone as a local anesthetic adjuvant for brachial plexus block: a systematic review and meta-analysis of randomized trials. *Br J Anaesth*. 2014;112(3):427-39.
18. Fredrickson MJ, Kilfoyle DH. Neurological complication analysis of 1000 ultrasound guided peripheral nerve blocks for elective orthopaedic surgery: a prospective study. *Anesthesia*. 2009 Aug;64(8):836-44.
19. Rahangdale R, Kendall MC, McCarthy RJ. The effects of perineural versus intravenous dexamethasone on sciatic nerve blockade outcomes: a randomized, double-blind, placebo-controlled study. *Anesth Analg*. 2014;118(5):1113-9.
20. Pani N, Routray SS, Mishra D, Pradhan BK, *et al.* A clinical comparison between 0.5% levobupivacaine and 0.5% levobupivacaine with dexamethasone 8 mg combination in brachial plexus block by the supraclavicular approach. *Indian J Anaesth*. 2017;61(4):302-7.
21. Srinivasa Rao Nallam. Interscalene Brachial Plexus Block: Comparison of Efficacy of Varying Doses of Dexamethasone Combined with Levobupivacaine: A Double-blind Randomised Trial. *Journal of Evolution of Medical and Dental Sciences*. 2014;3(25):6900-8.
22. Hanuman setty K, Hemalatha S, Gurudatt CL. Effect of dexamethasone as an adjuvant to 0.5% levobupivacaine in supraclavicular brachial plexus block for upper extremity surgeries. *Int J Res Med Sci*. 2017;5(5):1943-7.
23. Kilic E, Karsli B, Evrenos MK. The effects of application of 0.5% levobupivacaine together with 5 mg dexamethasone for infra-clavicular block in surgical treatment of forearm fractures. *Medical Science and Discovery*. 2017; 4(11):80-5.
24. Akkaya A, Yildiz I, Tekelioglu UY, *et al.* Dexamethasone added to levobupivacaine in ultrasound-guided transversus abdominis plain block increased the duration of postoperative analgesia after caesarean section: a randomized, double blind, controlled trial. *Eur Rev Med Pharmacol Sci*. 2014; 18(5):717-22.